

Le fratture dell'omero prossimale :  
diagnosi e trattamento

PROVA NON ESTRATTA

~~M. Berti~~

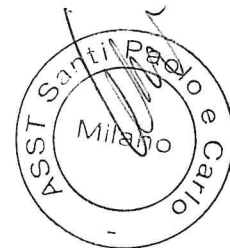
*[Handwritten signature]*



*[Handwritten signature]*

Prova pratica n. 2

## Inquadramento diagnostico e terapeutico delle fratture periprotetiche dell'anca



A blue ink signature consisting of a vertical line with a loop at the top and a horizontal stroke at the bottom.

A blue ink signature consisting of a horizontal line with a loop at the end.

PROVA ESTRATTA

A large, stylized black ink signature, likely 'Alessandro Ferretti', written in a cursive script.

Prova pratica n. 3

Le fratture sovracondiloidee del bambino

PROVA NON ESTIMATA

~~Abbatefalletti~~

*[Handwritten signature]*

*[Handwritten signature]*  
ASST Santi Paolo e Carlo  
Milano  
*[Handwritten signature]*